

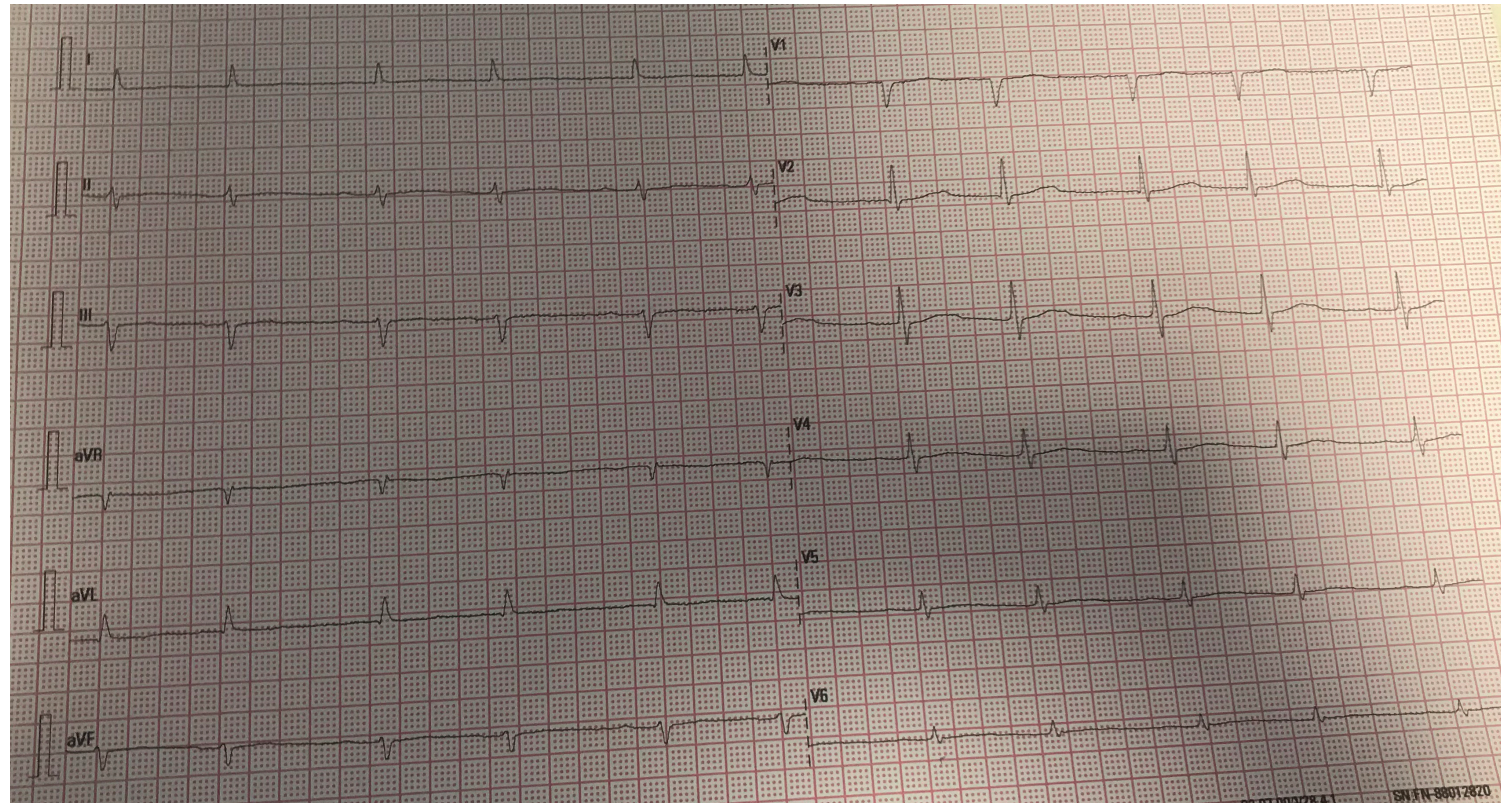
**A.S. 84 y/o male**  
**75 Kg – 170 cm – 26 Kg/m<sup>2</sup>**

# Clinical data

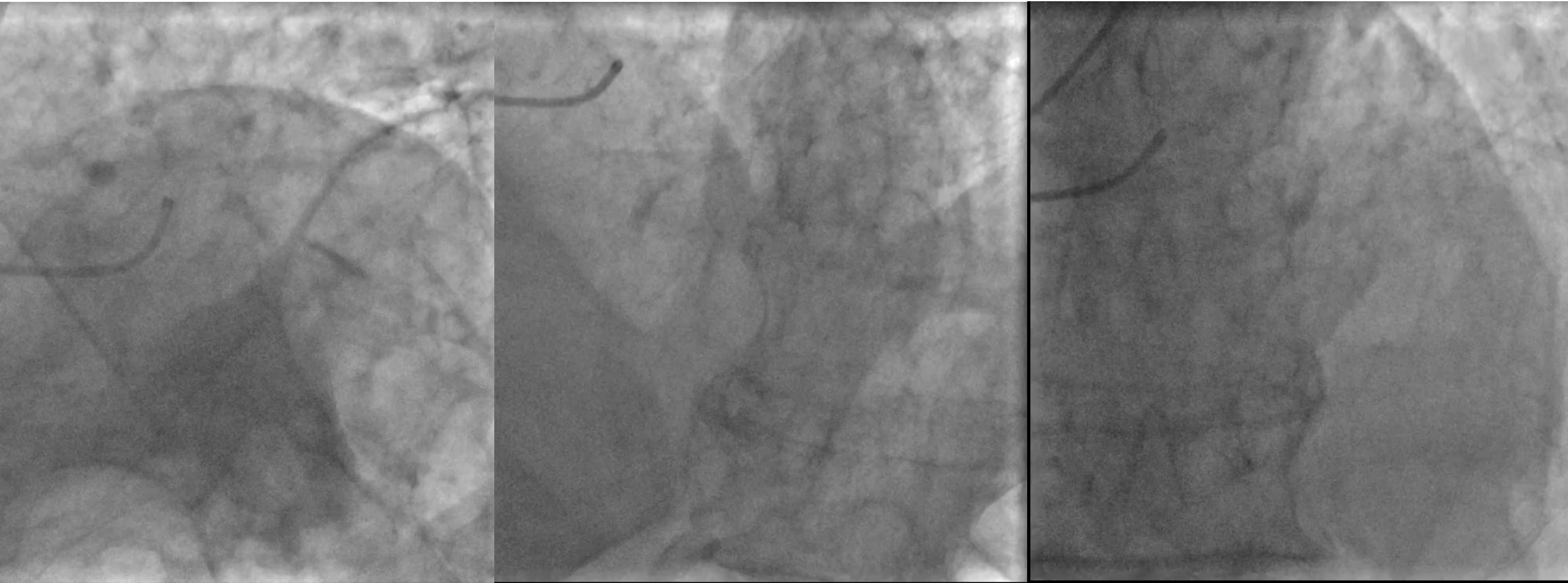
- Risk factors: Hypertension, dyslipidemia
- Medical history: paroxysmal Afib in NOAC; abdominal aortic aneurysm treated with EVAR (6 mo ago)
- Clinical presentation in ER: NSTEMI
- TT-Echo: LV of normal size and thickness; inferior hypokinesia, distal IVS + mid-distal anterior hypokinesia (EF 35%), primary moderate MR; minimal AR; moderately reduced RV function (FAC 40% and TAPSE 16 mm); moderate PH (PASP 40 mmHg)

# Laboratory

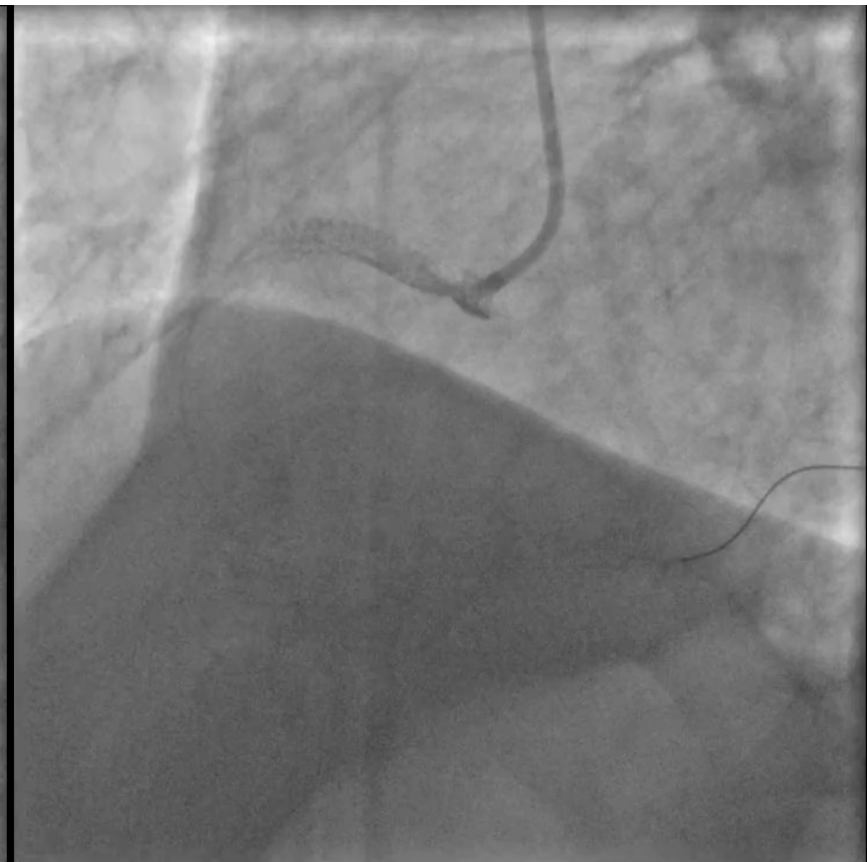
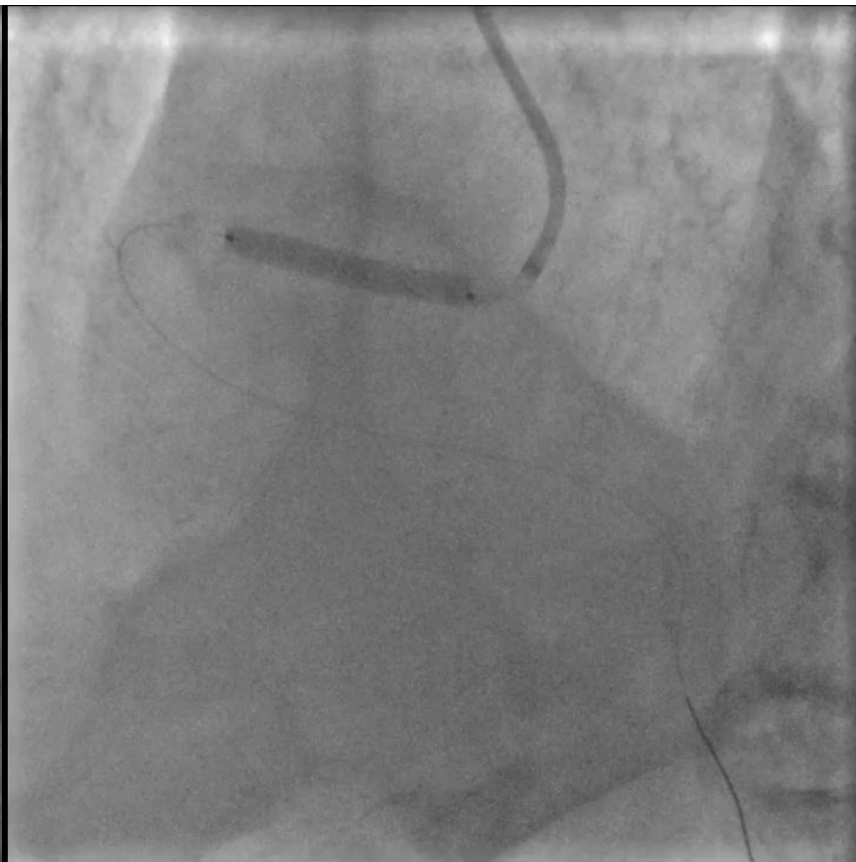
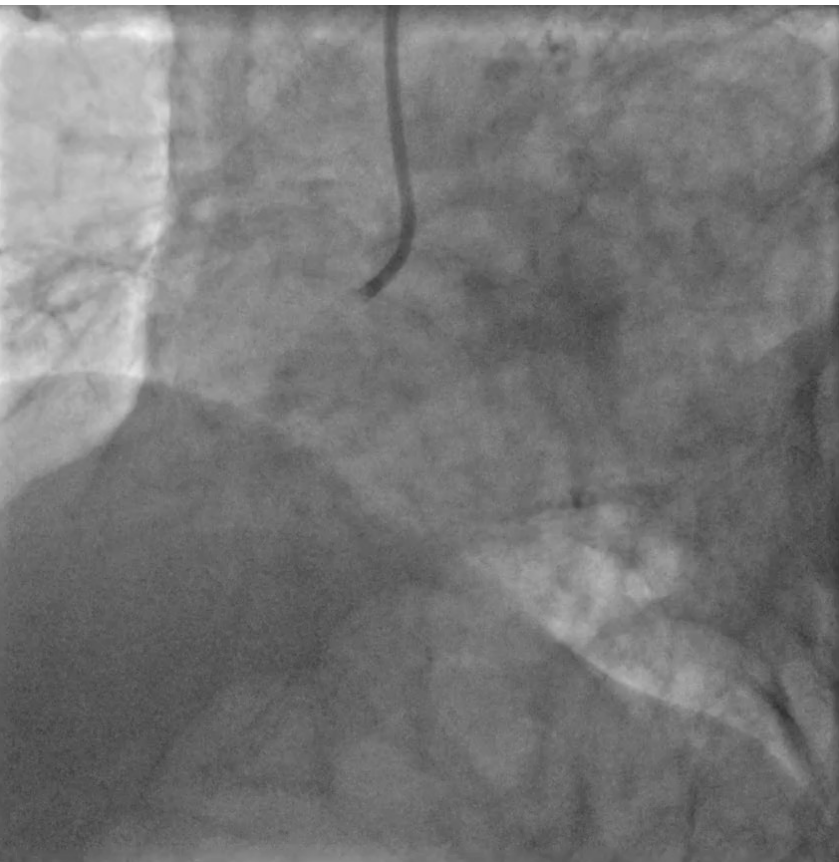- Lab: Hb 11.2 g/dL; PLT 253.000/uL; INR 0.99; creatinine 1.53 mg/dL; hsTn 1500 ng/L (v.n. < 57); K+ 3.6 meq/L

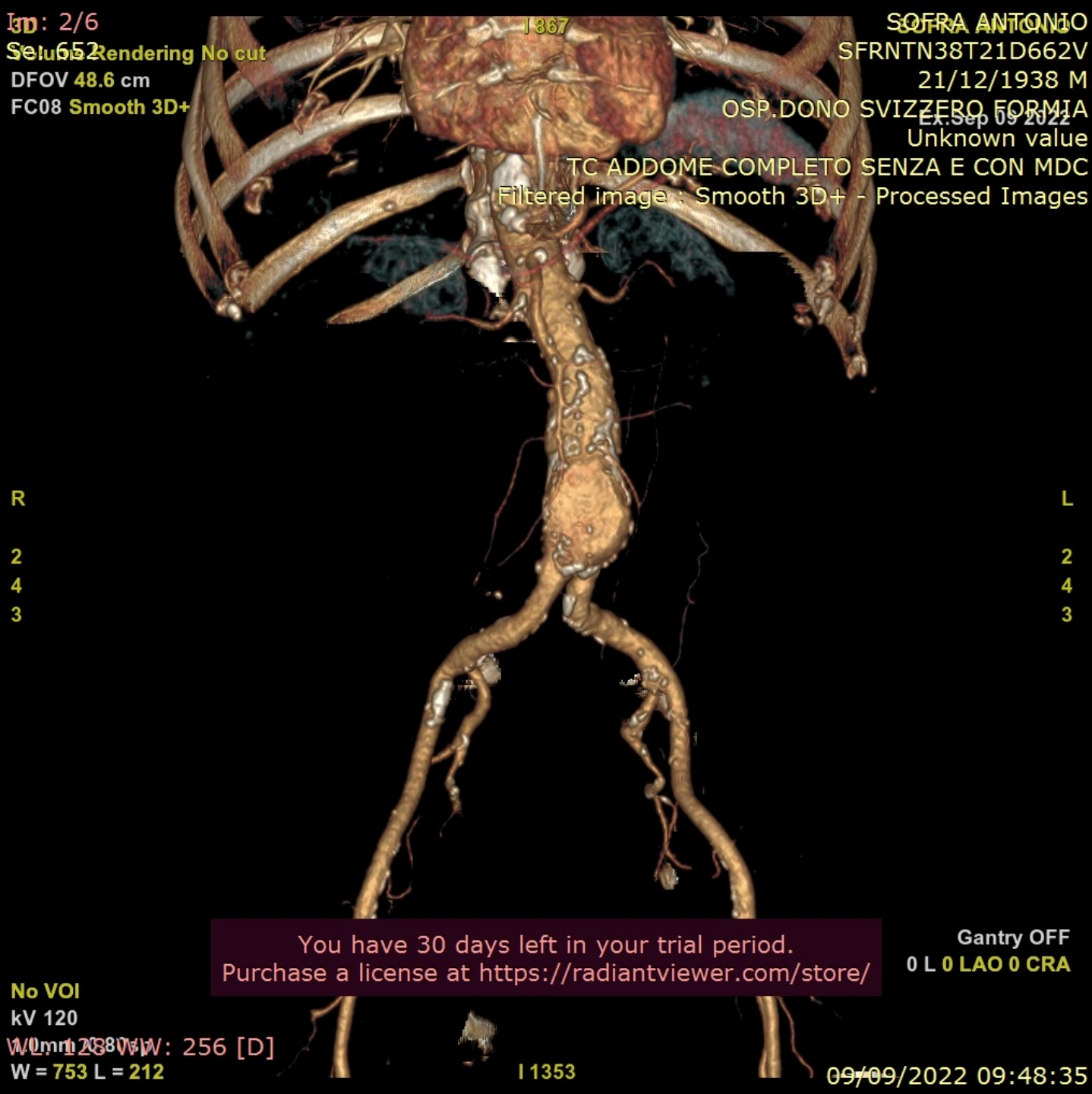


# Cath-Lab



# RCA PCI: Sirolimus DES 4.0 x 28 mm; NC 4.5 mm





- Right Iliac Artery: 11 mm
- Left Iliac Artery: 11 mm
- Right CFA: 8 mm
- Left CFA: 9 mm

You have 30 days left in your trial period.  
Purchase a license at <https://radiantviewer.com/store/>